



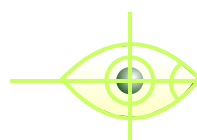If silicone oil is injected then these postural restrictions are not required, but the patient has to undergo another small operation a few weeks or a few months later to remove this silicone oil.

The surgical result of this condition is extremely good. Some of these patients have an impending or an early stage maculopathy in the other eye also and the patient should be observed and surgically treated in the other eye if he develops full thickness hole. The improvement in vision may take 6 to 12 months.

### Complications

One can have accelerated development of cataract following this operation and it may require cataract operation or sometimes cataract operation can be done along with vitrectomy.

In rare cases a macular hole can lead to retinal detachment and the treatment is along the same principals and they also do well.



## Drushti

Eye & Retina Centre  
& Rajvi Nursing Home

ISO 9001 : 2000 Certified

**Dr. Vatsal S. Parikh** M.S., D.O.M.S., F.C.P.S.

FELLOW SANKARA NETHRALAYA, (CHENNAI)

210-211, Radhe Vallabh C.H.S. (Formerly Modi Chambers),  
2nd Floor, French Bridge Corner, Opera House, Mumbai - 400 004.

Tel. : +91-22-2388 0505, 2380 4086, 2386 4191

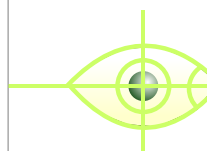
Resi.: 2367 7111, 2361 2996 • Fax : 2388 7738

Email : rajvi@vsnl.com • Website : www.drushti.com

Timing : Mon. to Fri. 3.30 to 8.30 p.m. Sat. 9 a.m. to 1 p.m.

*Donate Eyes, Restore Sight*

## MACULAR HOLE



## Drushti

Eye & Retina Centre  
& Rajvi Nursing Home



Putting 'EYE' before 'I'

Specialist in Diseases of Vitreous & Retina  
Lasers & Ultra Sonography & Microsurgery of Eye

**Macula** is the central most important part of the retina, which is required for central clear quality of vision. Occasionally, a hole may develop in this central part of the retina, which is called as macular hole. Initially, this condition was considered untreatable and patient would live with subnormal vision, but with advent of modern vitreoretinal procedures, this condition is now surgically treatable with good results in more than 90% of patients.

### What causes Macular Hole?

One of the common causes of macular hole is idiopathic- which is without any apparent cause and is usually seen in elderly people. It can often affect both eyes though in varying degrees. Other causes could be following trauma or following other retino-vitreous diseases in which the macula is pulled leading to hole formation.

This traction or pull on the macula is by the vitreous, which tends to condense in elderly people. The hole could be of various grades. The hole could be lamellar or partial thickness to full thickness and it can be graded from grade 1 to grade 4.

### What are the common Symptoms?

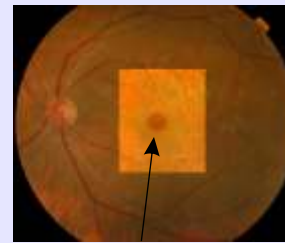
The patient would generally complain of loss of central clear vision and may say that in the central part of his visual field he sees a black spot or a scotoma. These patients also complain of a condition called metamorphopsia, which means that the objects may appear distorted or crooked and straight lines may appear wavy or broken.

### How to diagnose Macular Hole?

These patients should be examined by a retinal surgeon in detail using the various contact lens modalities and OCT is done in all cases to diagnose and monitor the progress. FFA (fundus fluorescein angiography) may be done for the diagnosis.

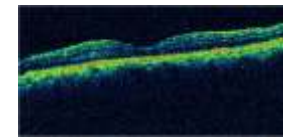
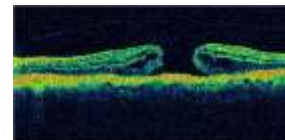
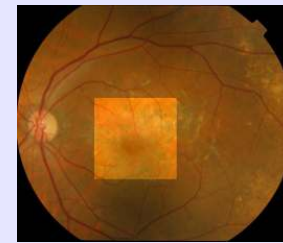
## FUNDUS PHOTOGRAPHS OF MACULAR HOLE

BEFORE SURGERY



Macular Hole

AFTER SURGERY



### What is the treatment of Macular Hole?

Till some years ago there was no treatment for this condition. But in the last few years there is a surgical treatment called Vitrectomy surgery where the vitreous gel with its outer most layer called posterior hyaloids, which is the cause of the pull on the retina leading to the hole formation, and the inner layer of the retina called the internal limiting membrane is removed. Special dye called Indocyanine green or trypan blue is also used during surgery. The result of the surgery is extremely good with the success rate of 90% to 95% for hole closure and with good improvement in the vision.

The surgery consists of vitrectomy and along with it there is an option of using silicone oil or special intra-vitreous gas. The gas is preferable because gas is temporary as it remains for a few days, gets absorbed and does not need removal or any further surgery. With gas, the patient has to be strictly in prone position (that is the head has to be kept low so that due to gravity the gas bubble rises towards the macula) and the patient has to maintain this position for at least 20 hours a day for 5-7 days.